

PT 342-343 Functional Neuroanatomy Worksheets

UNIT 2 Figure 9

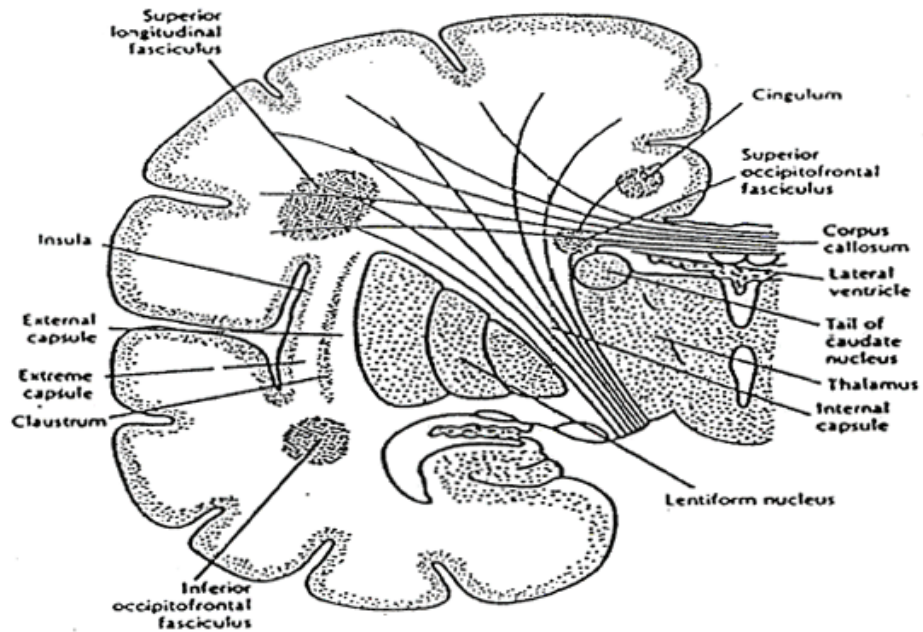


Figure 16-1. Coronal section through a cerebral hemisphere, indicating the positions of the larger bundles of association, commissural, and projection fibers.

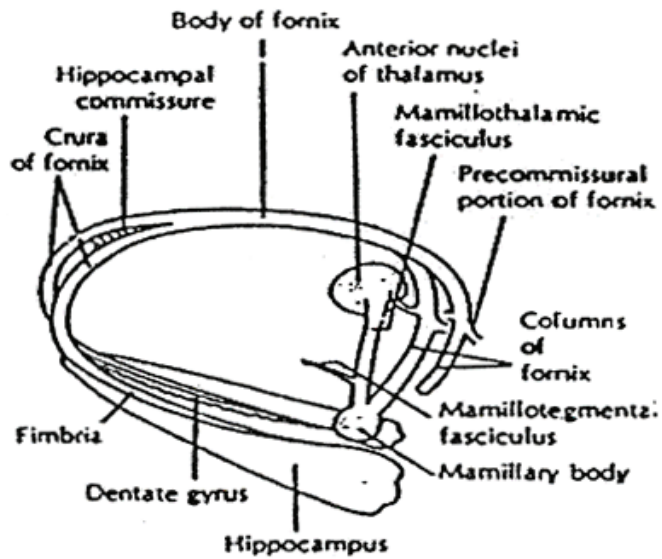


Figure 18-3. Fornix and related parts of the limbic system.